

Pre-Operative Assessment of the Size of the Herniated Lumbar Disc on MRI as a predictor of Surgical Outcome

Hesham Elshiekh^a, Inas M. Sweed^a, Ahmed M. Deabes^b, Nour Zaghlol^a

Abstract:

^a Department of Radiology, Benha faculty of medicine, Benha University, Egypt.

^b Department of Neurosurgery, Faculty of Medicine, Banha University, Egypt

Correspondence to: Nour Zaghlol. Department of Radiology, Benha faculty of medicine, Benha University, Egypt.

Email:

nourzaghlol2021@yahoo.com

Received: 6 March 2021

Accepted: 5 April 2021

Background: Lumbar intervertebral disc herniation (LDH) is the most common source of lumbar radiculopathy. Magnetic Resonance Imaging (MRI) is considered the diagnostic imaging procedure of choice for LDH as it can provide exquisite morphologic details of the disc abnormality. **The aim of this study** was to determine if baseline MRI findings, including disc herniation size, is associated with differential surgical treatment effect. **Method:** This study was conducted on Benha university hospitals on 36 patients who underwent lumbar discectomy to estimate the role of MRI as a predictor of surgical outcome (by comparison between preoperative and postoperative leg and back pain scores, as well as functional status measured using the modified Oswestry Disability Index (MODI)). **Results:** The ages of patients were 21-51± 36 years, 22 patients (61.1 %) were males and 14 patients (38.9 %) were females. All these patients suffered from back and leg pain and 69.44% of them with lower extremity pain, 77.78% of them with sciatica, hypoesthesia and/or leg weakness was reported in 36.11% of cases. **Conclusion:** It can be concluded that MRI finding especially disc size and disc height can predict the surgical outcome. Patients with larger disc herniation, on average, may have a higher likelihood of experiencing superior clinical outcomes following discectomy. Additional findings seem to support that a patient's preoperative functional score has the strongest influence on postoperative clinical outcome.

Keywords: Herniated; Lumbar; Disc; MRI

Introduction

Lumbar intervertebral disc herniation (LDH) is the most common source of lumbar radiculopathy. Magnetic Resonance Imaging (MRI) is considered the diagnostic imaging procedure of choice for LDH as it can provide exquisite morphologic detail of the disc abnormality (1).

Disc herniation refers to displacement of intervertebral disc material beyond the normal confines of the disc but involve less than 25 % of the circumference. Disc protrusions are a type of disc herniation in which the width of the base is wider than the largest diameter of the disc material which projects beyond the normal disc margins must not extend above or below the relevant vertebral endplates (2).

Lumbar disc herniation (LDH) represents a frequent situation in routine clinical practice. Primary clinical manifestations include motor and/or sensory deficit in distribution of the affected nerve root, encountered on the ground of referred low back and/or radicular pain. Conservative treatment should institute the first-line selection. Medication regimen, physical therapy sessions, and epidural spinal injections, come first. However, clinical failure of

conservative management dictates surgical intervention (3).

The efficacy of lumbar discectomy as a treatment for the functional impairments related to (LDH) has been well established in a number of studies (4). Although preoperative predictors of outcome following lumbar discectomy remain poorly defined, some studies have suggested that the size of the herniation as measured on a preoperative MRI is a reliable predictor of surgical outcome. Patients with larger size herniation (greater than 6 mm) will have better outcome following discectomy (5).

This study aimed to determine if baseline MRI findings including disc herniation size is associated with differential surgical treatment effect.

Patients and methods

This observational study was conducted in Benha university hospitals, during the period from January 2020 to December 2020, and conducted on 36 patients who underwent lumbar discectomy to compare between Preoperative and postoperative leg and back pain scores, as well as functional status measured using the modified Oswestry disability index (MODI) and estimate the

role of MRI as a predictor of surgical outcome

This study was approved by the Ethical Committee of Benha Faculty of Medicine.

Inclusion criteria:

- both sexes
- age >18 years
- patients who underwent lumbar discectomy

Exclusion criteria:

- Patients with malignancy
- patients who refused to be included in the study

All patients were subjected to complete history taking, complete examination and MRI

Magnetic Resonance Imaging (MRI):

- MRI lumbar spine axial T1,T2- Sagittal T1,T2
- Data collected from the MRI will be included the maximal anteroposterior dimension from the posterior annulus to the most dorsal extent of the LDH on an axial T2 image centered on the pathology, and the maximal disc height at the level of the herniation.
- A lumbosacral MRI (Magnetom Avanto 1.5T, Siemens, Harvey, IL

USA) without contrast was performed in all patients and its data were also recorded in the database. The MRI data included the level of the LDH (if present), presence or absence of osteophytes, annular tears, disc location in the axial plane (central, paracentral, foraminal, or extra-foraminal), disc herniation type (bulging, protrusion, or extrusion)

- **Disc size:** the maximal anteroposterior dimension from the posterior annulus to the most dorsal extent of the LDH on an axial T2 image centered on the pathology.
- **Disc height:** the maximal disc height at the level of the herniation at sagittal T2.
- Disc bulge was defined as the presence of disc tissue circumferentially (50%-100%) beyond the edges of the ring apophyses.
- Protrusion was present if the greatest distance, in any plane, between the edges of the disc material beyond the disc space was less than the distance between the edges of the base in the same plane.

- Extrusion was present when any one distance between the edges of the disk material beyond the disc space was greater than the distance between the edges of the base or when no continuity existed between the herniated disk material and the disc space

Surgical procedure

The surgical procedure was consisted of a unilateral laminectomy and discectomy. Operating microscope or loupe magnification was utilized according to surgeon preference and was not considered in the analysis of patient outcomes.

Intra-operative findings was recorded and consisted of the volume of disc material removed during the procedure. The volume of disc material removed was measured and correlated with the disc size on MRI.

Assessment of surgical outcome:

Postoperative clinical outcome as defined by leg and back pain scores, as well as functional status measured using the modified oswestry disability index (MODI) after about 12 weak from surgery

Statistical analysis:

The collected data was revised, coded, tabulated and introduced to a PC using Statistical package for Social Science (IBM Corp. Released 2017. IBM SPSS Statistics for Windows, Version 25.0. Armonk, NY: IBM Corp.). Data were presented and suitable analysis was done according to the type of data obtained for each parameter.

Descriptive statistics: Mean, Standard deviation (\pm SD) for numerical data. Frequency and percentage for non-numerical data. Shapiro test was done to test the normality of data distribution. Significant data was considered to be nonparametric. Analytical statistics: Student T Test was used to assess the statistical significance of the difference between two study group means. Chi-Square test was used to examine the relationship between two qualitative variables. Fisher's exact test: was used to examine the relationship between two qualitative variables when the expected count is less than 5 in more than 20% of cells. N.B: p is significant if <0.05 at confidence interval 95%.

Results

The ages of patients were (21-51 \pm 36 years), 22 patients (61.1 %) were males and 14

patients (38.9 %) were females (**table 1**). All these patients suffered from back and leg pain and 69.44% of them with lower extremity pain, 77.78% of them with sciatica, hypoesthesia and/or leg weakness was reported in 36.11% of cases

Sixteen of these of patients had L4-L5 disc herniation (44.44%) and 20 patients had L5-S1 disc herniation (55.56%) with regard to Laterality: (52.78%) had left herniation, 38.89 % right herniation, 8.33% were central disc herniation, (**table 2**).

According to herniation type, 44.44% of cases had protrusion, 25% of cases showed extrusion and 30.56% of cases had sequestration. Disc height was 8.75 ± 1.75 mm, disc size (AP length) was 8 ± 2 cm and disc volume extracted was 0.95 ± 0.5 cc, (**table 3**).

Pre-operative Vas Leg score was 6.36 ± 1.1 but 1.167 ± 0.307 , 12 weeks after surgery. The difference pre and post-operative was statistically significant and measured 5.19 ± 1.24 ($p < 0.0001$). Pre-operative Vas Back score was 4.58 ± 0.98 and 1.72 ± 0.73 12 weeks after surgery. The difference pre and post-operative was statistically significant and measured 2.86 ± 1.32 ($p < 0.0001$). Pre-operative MODI score was 59.11 ± 5.36 and 17.08 ± 2.62 weeks after

surgery. The difference pre and post-operative was statistically significant and measured 42.02 ± 6.76 ($p < 0.0001$), (**figure 1**).

MODI score difference was significantly different according to Herniation type as shown in table 4, We divided our subjects into two group according to MODI score difference, group A who had improvement equal or higher than 40 in MODI score and they were 20 patients, while group B who had improvement less than 40 in MODI score, were 16 patients. There was a statistically significant difference between both groups according to MODI score difference, Disc size, Disc height and Disc volume extracted, (**table 4**).

There was a strong positive correlation between MODI Score Difference and Disc size ($r=0.643$, $p < 0.0001$) and also Disc volume extracted ($r=0.7473$, $p < 0.0001$). There was a strong negative correlation between MODI Score Difference and Disc height ($r=0.507$, $p = 0.001$), (**table 5**).

Case (1): Female patient aged 35yrs, presented with left leg pain and numbness, MRI shows L5-S1 central and left para central disc herniation, L4-L5 diffuse posterior disc bulge and Disc degenerative changes, (**figure 2**)

Case 2: Female patient aged 36yrs, presented low back and leg pain, MRI shows L4-L5 focal central and right para central

disc herniation with caudal migration and severe spinal canal stenosis and severe right neural compromise, (**figure 3**).

Table (1) General characteristic

Age (years)	21-51(mean:36)		21-51(mean:36)
	Males	n (%)	22 (61.1)
Gender	Females	n (%)	14 (38.9)
BMI			26.7 ±4.6
Total			36

Table (2): Level and Laterality of Herniation in all cases

		N	%
Level of Herniation	L4/L5	16	44.44
	L5/S1	20	55.56
Laterality of Herniation	Right	14	38.89
	Left	19	52.78
	Central	3	8.33

Table (3): Herniation type & properites in all cases

		N	% / SD
Herniation type	Protrusion	16	44.44
	Extrusion	9	25
	Sequestration	11	30.56
Disc height mm		8.75	±1.75
Disc size (AP length) cm		8	±2
Disc volume extracted cc		0.95	±0.5

Table (4) comparison between two groups according to MODI score difference, Disc size, Disc hight and Disc volume extracted

	Group A (MODI score difference \geq 40)	Group B (MODI score difference $<$ 40)	T	P
N	20	16	--	--
MODI difference	46.7	36.19	7.08	< 0.0001
Disc size	8-10	6-8	4.63	< 0.0001
Disc height	8.5-10.5	7-8.5	3.71	0.0004
Disc volume extracted	.9-1.45	.45-.9	8.53	< 0.0001

Table (5): Correlation between MODI Score Difference and Disc size, Disc hight and Disc volume extracted

MODI Score Difference	R	P
Disc size	0.643	< 0.0001
Disc hight	0.507	0.001
Disc volume extracted	0.7473	< 0.0001

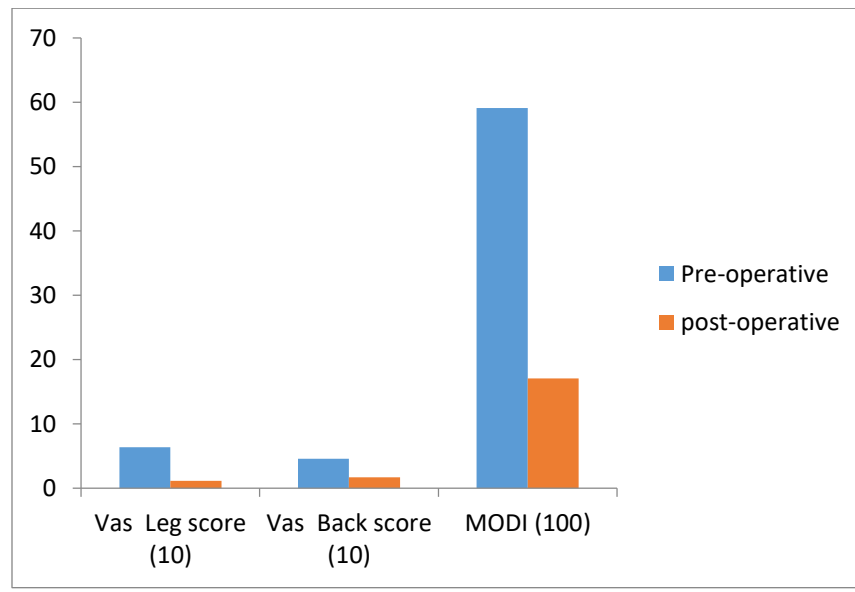
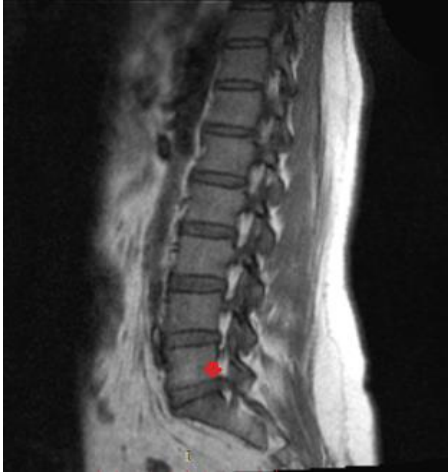
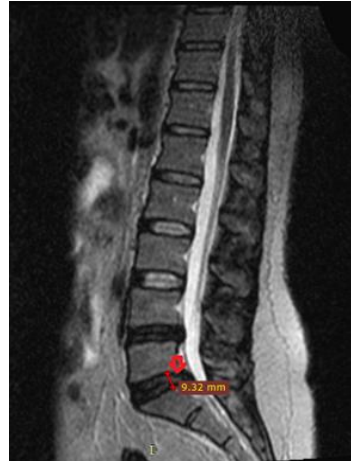
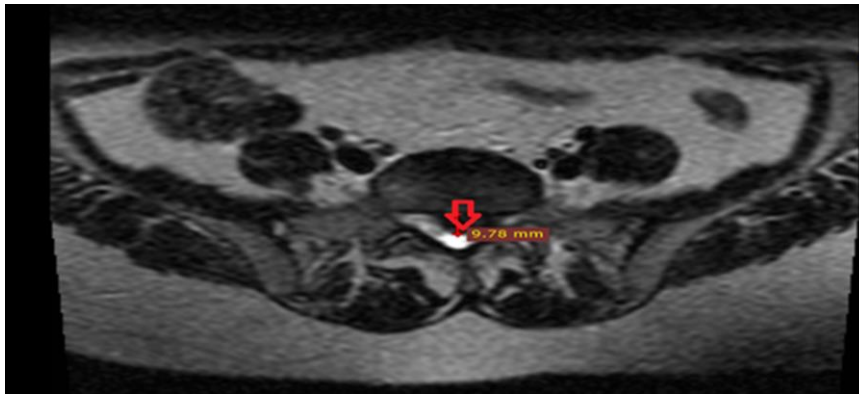
Figure (1): comparison between Pre-operative and post-operative (12 w) Vas Leg score, Vas Back score and MODI score



(A) Sagittal T1: L5-S1 disc herniation, L4-L5 disc bulge and Disc degenerative changes noted.

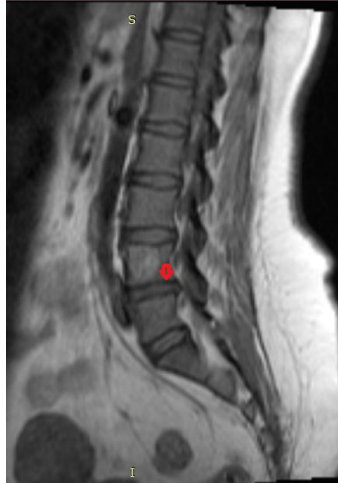

(B) Sagittal T2: L5-S1 disc herniation with moderate to severe spinal canal stenosis. Height of disc herniation=9.32mm

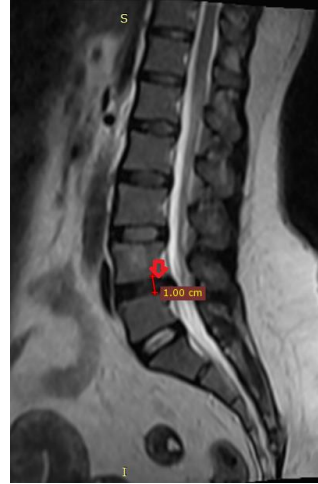


(C) Axial T2: L5-S1 central & left paracentral disc herniation, obliterating the hyperintense signal of the epidural fat, and encroaching upon the left lateral neural recess and the related pre-exit nerve roots. Size of herniation=9.78mm Volume of disc (surgically extracted)=1.45c

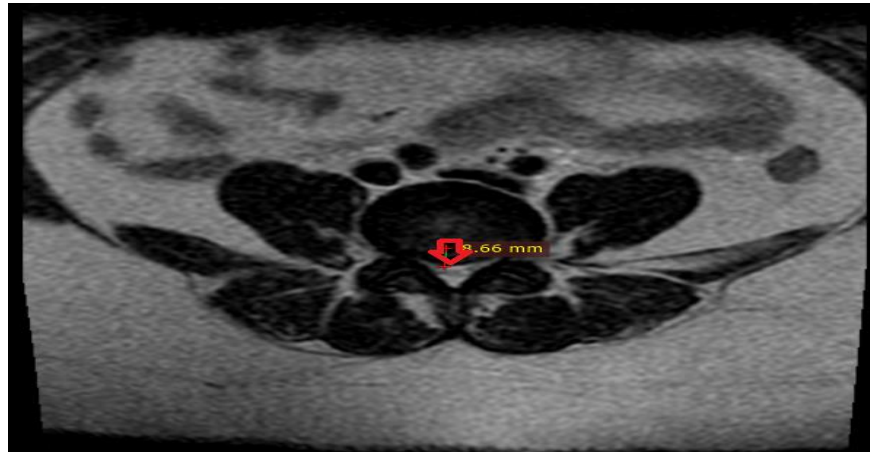Figure 2: (A, B, C)



(A) Sagittal T1: L4-L5 disc herniation



(B) Sagittal T2: L4-L5 disc herniation with caudal migration and severe spinal canal stenosis and severe neural compromise. Height of disc hereniation=10mm



(C) Axial T2: L4-L5 central and right para central disc herniation indenting the ventral aspect of the thecal sac, and encroaching upon RT neural foramen and the related exit nerve root. Size of herniation=8.66mm. Volume of disc(surgically extracted)=1cc

Figure 3: (A, B,C)

Discussion

The ages of patients were (21-51±36 yrs), and 22 patients (61.1 %) were males and 14 patients (38.9 %) were females, in the same line with that study (5), where sixty-three patients were included in this study. The mean age was 44 ± 12 years. There were 39 men (61.9%) and 24 women (28.1%). In another study (6), the mean age was 39.3 ± 9.9 years (Range:22-64 yrs). Eighty two (70%) were males and 35 (30%) were females.

According to associated symptoms in the present study, all these patients suffered from back and leg pain and 69.44% of them with lower extremity pain, 77.78% of them with sciatica, hypoesthesia and/or leg weakness were reported in 36.11% of cases. In previous study (7), neurological disorders presenting as hypoesthesia and weakness in the innervation zone of a compressed spinal nerve root were observed in 33.3% of patients.

According to Level of Herniation in the present study, 55.56% of patients were at level L5/S1 and 44.44% at level L4/L5. With regard to Laterality: (52.78%) had left herniation, 38.89 % right herniation, 8.33% were central disc herniation. It was reported

that most of the operated levels were L4-5 (47%) and L5-S1 (47.9%) (6). In another study (8), 14 (3.8%) had an L3-L4 herniation, 185 (50.3%) had an L4-L5 herniation, and 169 (45.9%) had a herniation at the L5-S1 level.

According to Herniation type in the present study, it was Protrusion in 44.44% of cases, Extrusion in 25% of cases and Sequestration in 30.56% of cases. Disc height was 8.75 ± 1.75 mm , Disc size (AP length) was 8 ± 2 cm and Disc volume extracted was 0.95 ± 0.5 cc, It was similar to previous study (7), they reported that the herniation type (protrusion, extrusion, or sequestration) was determined from the MR scans. Protrusion (47.5%) was the most common type, while extrusion and sequestration

Pre-operative Vas Leg score in the present study was 6.36 ± 1.1 and 1.167 ± 0.37 12 weeks after surgery. The difference pre and post-operative was statistically significant and measured 5.19 ± 1.24 ($p < 0.0001$). Pre-operative Vas Back score was 4.58 ± 0.98 and 1.72 ± 0.73 12 weeks after surgery. The difference pre and post-operative was statistically significant and measured 2.86 ± 1.32 ($p < 0.0001$). Pre-operative MODI

score in the present study was 59.11 ± 5.36 and 17.08 ± 2.62 weak after surgery. The difference pre and post-operative was statistically significant and measured 42.02 ± 6.76 ($p < 0.0001$). MODI score difference was significantly different according to Herniation type ($p < 0.0001$), a researcher and his colleagues (5), was the first to use Vas back and Leg score to estimate the role of preoperative role of MRI in determination of disc size and height and volume extracted as predictor of surgical outcome. In their study, the VAS back pain scores decreased by 3.4 points ($p < 0.001$), while the VAS leg pain scores decreased by 5.5 points ($p < 0.001$), and MODI scores decreased 38.4 points ($p < 0.001$)

In the present study, we divided our subjects into two group according to MODI score difference, group A who had improvement equal or higher than 40 in MODI score and their number was 20 while group A who had improvement less than 40 in MODI score and their number was 16, there was a statistically significant difference in the present study between both groups according to MODI score difference, Disc size, Disc height and Disc volume extracted and, a strong positive correlation in the present study between MODI Score Difference and Disc size ($r = 0.643$, p

< 0.0001) and also Disc volume extracted ($r = 0.7473$, $p < 0.0001$). There was a strong negative correlation between MODI Score Difference and Disc height ($r = 0.507$, $p = 0.001$). Previous work has studied the influence of the size of disc herniation on surgical outcomes. In a prospective study that included 48 surgically treated patients, it was found that all fair and poor outcomes following discectomy were in patients with disc herniation smaller than 6 mm in anteroposterior dimension (1).

The results of this study can be used to improve preoperative patient education. It can be concluded that patients with larger disc herniation, on average, may have a higher likelihood of experiencing superior clinical outcomes following discectomy. Additional findings seem to support that a patient's preoperative functional score has the strongest influence on postoperative clinical outcome. Further study may be warranted to prospectively investigate the interplay between imaging findings, baseline pain and dysfunction, and postoperative outcomes for lumbar disc herniation.

Conclusion

MRI finding especially disc size and disc height can predict the surgical outcome. Patients with larger disc herniation, on

average, may have a higher likelihood of experiencing superior clinical outcomes following discectomy. Additional findings seem to support that a patient's preoperative functional score has the strongest influence on postoperative clinical outcome.

References

1. Lurie JD, Moses RA, Tosteson ANA, Tosteson TD, Carragee EJ, Carrino JA, et al. Magnetic resonance imaging predictors of surgical outcome in patients with lumbar intervertebral disc herniation. *Spine (Phila Pa 1976)*. 2013;38(14):1216.
2. Fardon DF, Williams AL, Dohring EJ, Murtagh FR, Rothman SLG, Sze GK. Lumbar disc nomenclature: version 2.0: Recommendations of the combined task forces of the North American Spine Society, the American Society of Spine Radiology and the American Society of Neuroradiology. *Spine J*. 2014;14(11):2525–45.
3. Kapetanakis S, Gkantsinikoudis N, Charitoudis G. The role of full-endoscopic lumbar discectomy in surgical treatment of recurrent lumbar disc herniation: a health-related quality of life approach. *Neurospine*. 2019;16(1):96.

To cite this article: Hesham Elshiekh , Inas M. Sweed
Pre-operative assessment of the size of the herniated lumbar disc and its effect on the surgical outcome. *BMFJ* 2021;38(1): 368-379. DOI: 10.21960/bmfj.2021.38.1.368-379

Relat Res. 2015;473(6):1963–70.

5. Derick C, Leonard DA, Schoenfeld AJ, Harris MB, Zampini JM, Bono CM. Relationship between size of disc and early postoperative outcomes after lumbar discectomy. *Arch Orthop Trauma Surg*. 2017;137(6):805–11.
6. Hamada S, Abou-Zeid A. Clinical and Surgical Correlation with MRI Findings in Herniated Lumbar Disc: Towards Clinical and Surgical Application of the Current Classification Oriented Understanding of the Morphology of the Herniated Lumbar Disc. *Egypt Spine J*. 2015;14(1):32–45.
7. Konieczny MR, Reinhardt J, Prost M, Schleich C, Krauspe R. Signal intensity of lumbar disc herniations: correlation with age of herniation for extrusion, protrusion, and sequestration. *Int J spine Surg*. 2020;14(1):102–7.
8. Gupta A, Upadhyaya S, Yeung CM, Ostergaard PJ, Fogel HA, Cha T, et al. Does size matter? An analysis of the effect of lumbar disc herniation size on the success of nonoperative treatment. *Glob Spine J*. 2020;10(7):881–7.